

Histofreezer®

A Study of a New Method of Cryosurgical Treatment of Verrucae Plantaris

James C. Ricketti, DPM, DABPO, FACFO, FAAPSM,* and R. Sam Niedbala, PhD†

Abstract: Histofreezer® (SolarCare Technologies, Bethlehem, PA) is a new cryogenic treatment modality for treating warts and other dermal abnormalities. The authors have investigated the use of Histofreezer® for the treatment of verrucae plantaris. In three separate studies, patients were treated with the Histofreezer® alone, Histofreezer® plus 17% salicylic acid post-cryogenic treatment, and Histofreezer® plus 27% salicylic acid/ 17% lactic acid post-cryogenic treatment. Results showed that there was a direct increase in resolution rates varied from 44.6% to 86.2%. Also found was that the Histofreezer® is most effective on verrucae plantaris less than 5 mm in size. The Histofreezer® provided a convenient method for the treatment of verrucae plantaris with most warts resolving within 2 to 4 weeks when combined with a salicylic acid treatment. **Key words:** Histofreezer®, cryogenic, verrucae plantaris.

“At least one in every fourteen Americans will develop a wart this year, and many of those viruses will present themselves on the plantar aspect of the feet.”¹ Current treatment modalities include surgical, chemical, and immunologic techniques. At this time, there is no true cure for this virus. However, our investigations suggest a new cryosurgical treatment for verrucae plantaris that, if used properly, will give a physician a 65-86% resolution rate with a very low recurrence.² This cryosurgical treatment is called Histofreezer®‡. Historically, the cryosurgical modalities that have been used for treatment of verrucae were dry ice, nitrous oxide, and the very popular liquid nitrogen. All of these modalities freeze the tissues at temperatures colder than -60°C, thus, tissue destruction occurs. These cryosurgical modalities are approximately 80% effective when used correctly and have a 20% recurrence rate.³ Histofreezer® freezes at temperatures warmer than -60°C, thus it may be theorized that no tissue destruction occurs with the Histofreezer®. Histofreezer® does not burn the tissue because the temperature is not cold enough to produce tissue destruction. No patient in the study experienced any tissue damage or scarring.

Verrucae plantaris are benign, well-circumscribed lesions that characteristically bleed pin-pointedly upon paring. They are single or multiple in nature and are characterized by excruciating pain upon bearing weight, especially when a person rises after being seated or resting for a period of time.⁴ These lesions can occur on any aspect of the plantar sole or webspace but most frequently occur over the pressure points, such as heels and metatarsal heads.⁵

Plantar warts are caused by the human papillomavirus (HPV). At least 55 types of HPV have been identified, but the two most common types of viruses that cause plantar warts are HPV-1 and HPV-4.⁶ An irritation by a stone bruise, shell cut, splinter, or other foreign body may introduce the virus into the skin. Likewise, a biomechanical breakdown of the foot may also make the skin vulnerable to the invasion of the virus. A wet, hot shoe environment allows the virus to survive and thrive.

Blacks and diabetics appear to be spared from the HPV viruses. The virus is contagious, but the patient must be susceptible to the virus for it to spread. HPV incubation time ranges from 4 weeks to 20 months.⁷ Studies show that 67% of all warts will spontaneously resolve within a 2-year period without treatment, but large lesions on the plantar weight-bearing surfaces are quite debilitating and require treatment for normal ambulation. The ideal treatment should be risk-free, non-scarring, and painless. This article reports on the use of Histofreezer® for the removal of plantar verrucae.

*From *Hamilton Square, New Jersey, and SolarCare Technologies Corporation, Bethlehem, Pennsylvania.*

Reprint requests: Dr. James C. Ricketti, 2273 State Highway 33, Suite 204, Hamilton Square, NJ 08690.

Histofreezer® is a registered trademark of STC Technologies, Inc. Manufactured by: Utermohlen, Koninklijke Utermohlen NV, Utrecht, The Netherlands, U.S. Patent Number 4865028.

Materials and Methods

Patients were solicited for treatment through advertisements in the local newspaper. The advertisement did not exclude age, sex, race, size of lesion, or previous treatment. The study was broken down into three phases. Study I was performed using Histofreezer® alone as described by the manufacturer. Study 2 was performed using Histofreezer® followed by a 17% salicylic acid preparation, and study 3 was performed using Histofreezer® followed by a 27% salicylic acid/17% lactic acid preparation.

Study I was performed on 32 patients who had 65 lesions measuring 1 to 20 mm in diameter. The average diameter was 7.8 mm. The types of lesions ranged from solitary to multiple and mosaic patterns. The average age of the patients was 31 years but ranged from 9 to 49. Eighty percent of these lesions were previously treated chemically or surgically.

Study 2 was performed on 25 patients with 34 lesions measuring 1-40 mm in diameter, with the average being 9.40 mm in diameter. The average age of the patients was 29 years, with a range from 9 to 49. Many of these patients failed study I and had lesions measuring greater than 5 mm in diameter.

Study 3 was performed on 13 new patients who had not undergone any previous wart treatment. These patients had a total of 29 warts that were 1-20 mm in diameter (the average size was 4 mm). The average age of these patients was 20 years, and the range in age was 4 to 51 years.

Histofreezer® is a cryogen that uses an environmentally safe mixture of dimethyl ether and propane.

The spraying of these gases through an applicator onto a foam bud can produce a temperature of -57°C via heat of vaporization. (The mechanisms of cryosurgery are demonstrated in Fig. 1.) The Histofreezer® was invented in 1987 by a Dutch physician, Dr. Willem Swart, who was searching for an alternative to liquid nitrogen. The Histofreezer® also has a warmer freezing temperature (-57°C) versus liquid nitrogen (-196°C), which appears more easily tolerated by patients with minimal risk of scarring, blistering, or depigmentation.

Upon examination and acceptance into the study, the patients' lesions were circled and measured. At each treatment, the size of the wart was measured. These measurements were an accurate way to document the resolution of the wart. The lesions were then debrided to pinpoint bleeding; and the bleeding was coagulated using a StyptoCaine (Pedinol Pharmacol Corp., Farmingdale,

NY) solution (Fig. 2). Silver nitrate was not used because it was found to be irritating to the patient if used in combination with the Histofreezer® treatment. The patient was placed in an appropriate position so that the application of the Histofreezer® was in a dorsal to plantar position. The bud on the Histofreezer® was energized, with the can held in an upright position until the cryogen dripped from the polyester tip. The can was then turned 90° to the lesion. The applicator bud tip was applied to the lesion for approximately 40 seconds (Fig. 2). The application bud will maintain a temperature of -57°C for up to 120 seconds. Therefore, up to three applications may be applied per lesion if needed (Fig. 1). For example, if a lesion is 1.5 cm in diameter, divide the lesion into three sections of 5 mm in width. The width of the bud is 5 mm in diameter. Thus, three applications may be applied to the same lesion to treat the verrucae, remembering to always oversize the treatment onto healthy tissue.

Freezing occurs in spherical form (depth = width)

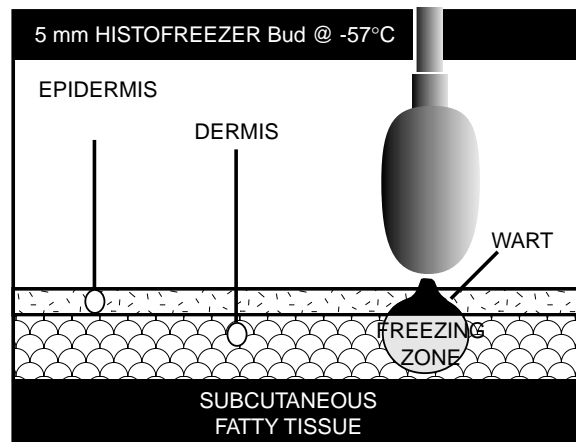


Fig. 1. Basics of cryosurgery.

The Histofreezer® can produce a sensation of cold when applied. The sensation felt by the patient upon application of the energized Histofreezer® bud is initially very cold followed in 10 to 20 seconds by numbness or tingling.

The area of treatment is critical because the density of tissue on the plantar foot for an adult and a child may vary. The following adage applies: the thicker the tissue, the longer the treatment and the thinner the tissue, the shorter the treatment. The average treatment time is 40 seconds. Thus, a plantar aspect of a toe may be treated for 30 seconds compared to one on the plantar aspect of the heel (which is thicker tissue and should be treated for up to a minute). However, the Histofreezer® package insert recommends 40 seconds.

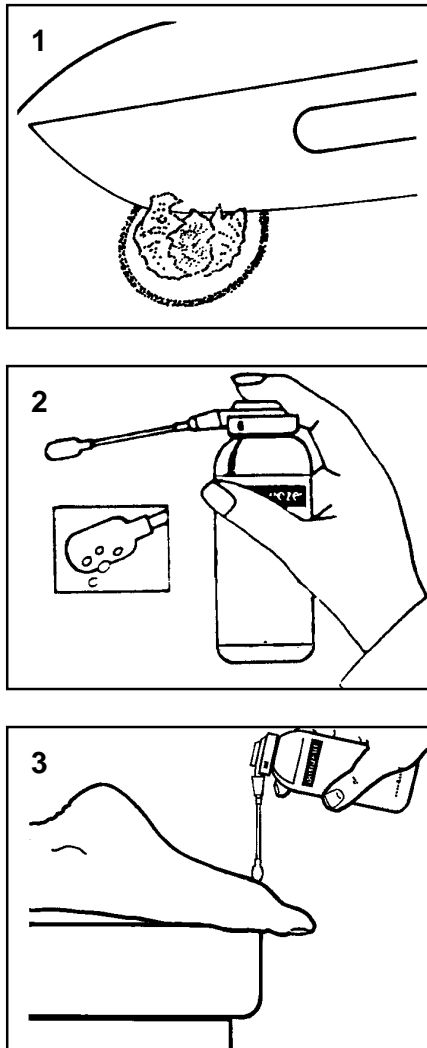


Fig. 2. Instructions for Histofreezer® from package insert. 1. Debride the lesion to pinpoint bleeding. The bleeding is then coagulated using a StyptoCaine solution. 2. Remove the protective cap from the canister; depress the valve. Keep the canister upright while saturating the applicator with cryogenic liquid. Release the valve when droplets start to form on the applicator tip (3-5 seconds). 3. Have the patient expose the surface to be treated upwards. Hold can firmly with finger off the valve. Point the applicator straight down, perpendicular to the floor, and press to the wart for 40 seconds.

All lesions were overtreated onto normal tissue so that freezing of both normal tissue and verrucae were accomplished. It is critical that the Histofreezer® be held in a dorsal to plantar position. The cryogen is never sprayed or dripped directly on the skin. The polyester applicator

should always be used because a second or third degree burn may occur.

It must be noted that in all three phases of the study, the blister is not expected with this treatment. If the skin does blister after treatment, then an error in method was performed. However, with other types of verrucae, such as vulgaris and condyloma acuminatum, and other conditions, such as molluscum contagiosum, blistering may occur and is part of the normal treatment process.

The Histofreezer® treatment was performed once every 14 days. No topical medication was applied to the lesion in studies 2 and 3 until the day after treatment. The treated area does not need to be covered or kept dry for the first 24 hours of treatment with this modality.

Results

In study I (Table 1), 32 patients were treated for 65 warts averaging 7.08 mm in diameter. They ranged from a single lesion to multiple and mosaic patterns. The results showed that, of the 65 warts treated every 14 days with the Histofreezer®, 29 warts resolved at a 44.6% resolution rate. The average number of treatments was four. However, of interest in study I is that 32 lesions treated were less than 5 mm in diameter. After 3.13 treatments, 69% of these warts resolved (Table 2).

Table 1. Study 1*

No. of patients	32
No. of warts	65
Average age of patients (years)	31
Average size of warts (mm)	7.08
Total no. of warts	65
Total no. resolved	29
Percent resolved	44.6

*Patients were treated with Histofreezer® by freezing the wart site according to the package insert directions over 8 weeks.

Table 2. Study 1: Results of Histofreezer® on Lesions ≤5 mm

No. of patients	32
No. of warts	32
Average age of patients (years)	31
Average size of warts (mm)	<5.0
Total no. of warts	32
Total no. resolved	22
Percent resolved	69.0

In study 2 (Table 3), 25 patients were treated for 34 warts. Warts averaged 9.40 mm in diameter. They ranged from single to multiple and mosaic patterns. These patients were treated every 14 days with the Histofreezer® and a 17% salicylic acid solution twice a day, beginning the day after cryogenic treatment. The results showed that, of the 34 warts treated, 22 resolved at a 64.7% resolution rate, with the average number of treatments being 2.59.

Study 3 (Table 4) consisted of 13 patients with no previous history of wart treatment, with a total of 29 warts measuring on average 4 mm. The verrucae appeared as single or multiple mosaic patterns. These patients were treated every 14 days with Histofreezer®. After treatment with cryogen, the patients applied a 27% salicylic acid/17% lactic acid gel twice a day on the day following treatment with the Histofreezer®. The results showed that of the 29 warts treated, 25 resolved at an 86.2% resolution rate, with the average number of treatments being 2.10.

In summary, of the total 78 patients treated in the three studies, it was found in a 12-month follow-up period that only four patients showed a recurrence of the verrucae plantaris. It should also be noted that of those patients, two had total resolution within two treatments of reapplication of Histofreezer® alone. In addition, the other two patients had the wart surgically excised. Thus, less than a 2% recurrence rate can be reported using Histofreezer® on verrucae plantaris if one includes the 12-month post-treatment period with Histofreezer®. There was no reported scarring on any of the patients at any time during the study. As previously stated, the temperature produced by the Histofreezer® is not cold enough to cause permanent tissue damage.

Table 3. Study 2*

No. of patients	25
No. of warts	34
Average age of patients (years)	29
Average size of warts (mm)	9.40
Total no. of warts	34
Total no. resolved	22
Percent resolved	64.7

*Patients were treated with Histofreezer® by freezing as directed, followed by daily applications of 17% salicylic acid formula.

Discussion

The theory of application of a cryogen is clearly described in numerous textbooks on cutaneous surgery.⁸ Using the Histofreezer®, dimethyl ether and propane is expelled onto a polyester swab. The temperature of the

swab will drop to -57°C via the heat of vaporization of the gases. If this bud is applied to the verrucae and surrounding skin, and pressure is maintained for 40 seconds, the verrucae will freeze. Thus, the depth of freezing is proportional to the width of the bud.

The Histofreezer® bud measures 5 mm in diameter. Therefore, the width and depth of the freeze is 5 mm. This has been shown by histologic section of pretreated Histofreezer® warts in our research. The depth of the cell lysis is directly proportional to the width of the bud. Since cells are composed of 89% water, this lower temperature will freeze and expand the cellular contents. Thus, the verrucoid cells with its surrounding normal cellular milieu will freeze and be destroyed. It is the mixture of the normal cellular contents with the destroyed verrucoid cells that causes an immune responses, thus, producing a foreign body reaction. This antigen antibody affect will ultimately eradicate the virus with the sloughed tissue.

Table 4. Study 3*

No. of patients	13
No. of warts	29
Average age of patients (years)	20.1
Average size of warts (mm)	4
Total no. of warts	29
Total no. resolved	25
Percent resolved	86.2

*Patients were treated with Histofreezer® according to the package directions, followed by daily treatment with a formula containing 27% salicylic acid and 17% lactic acid.

The direct advantage the Histofreezer® has over liquid nitrogen is that the Histofreezer® will freeze at a much warmer temperature (-57°C) and has greater accuracy in the application because of the swabs provided. Previously, Rees recommended superficial freezing every 2 weeks with liquid nitrogen as more effective and safer than prolonged deeper freezing.⁹ The Histofreezer® also recommends freezing every 2 weeks.

The Histofreezer® will produce an immediate blanching of the skin, followed by a tingling and possible stinging sensation over the subsequent 24-hour period, followed by a numbness over the lesion in the subsequent days. The numbness is the result of freezing the cutaneous nerves that lie in the dermis beneath the frozen verrucae.

Because plantar warts can cause considerable discomfort, active patients may want immediate treatment, even though 67% of the warts may eventually resolve. Conservative chemical treatments that involve the least amount of discomfort, inconvenience, expense, and risk of scarring should be considered first.

In reviewing the literature, the resolution ratios of the most popular treatments are not comparable. Bart et al. report a 60% resolution rate using a 17% salicylic acid in a transdermal delivery form.¹⁰ The average treatment time for resolution was 12 weeks. Bunney et al. reported that verrucae treated with liquid nitrogen, salicylic acid, and lactic acid and other topical chemicals showed cure rates of approximately 65%, 45% for mosaic plantar warts and 84% for simple warts, with a treatment period of 4-6 weeks.¹¹ McBurney and Rosen reported a laser cure rate of 81% for lesions that were stubborn and did not reappear within a 12-month period of time.¹² All other laser studies show higher resolution rates with little follow-up data and poor tracking of patients beyond 6 months. Apfelberg et al. reported only a 72% cure rate of verrucae plantaris using a CO₂ laser with a 60-month follow-up period.¹³ Resolution rates using podophyllin and canthone are not reported, due to the fact that they have been withdrawn from the market by the Food and Drug Administration.

It can be concluded from this study that for a lesion 5 mm or less in diameter, Histofreezer[®] treatment gives a 60% resolution rate in a 6-week period. This is quite acceptable and is within the normal standards, as compared to other cryochemical, methods.

For lesions that measure 5 mm and greater, a combined treatment of 17% salicylic acid and Histofreezer[®] is recommended to give a 64% resolution rate in 5.18 weeks of treatment. Previous studies on salicylic acid show that with lesions that measure 5 mm and greater, 17% salicylic acid would be effective 60% of the time with an average of 12 weeks of treatment. Thus, it can be concluded that the salicylic acid combined with the Histofreezer[®] would eradicate the verrucae in much less time. This method is more rapid than using salicylic acid alone. Higher concentrations of salicylic acid in combination with Histofreezer[®] treatment produce resolution rates up to 86.2% in 4 weeks.

Conclusion

Histofreezer[®] is safe, convenient, and effective for the treatment of verrucae plantaris. It produces acceptable resolution rates when performed properly and will produce very little discomfort and little risk of scarring. The comparable effectiveness, plus the portability of the product, makes the Histofreezer[®] an important tool for clinicians.

References

1. Robbins JE: Primary podiatric medical book. p. 302. WB Saunders, Philadelphia, 1994
2. Niedbala RS: FDA study on Histofreezer[®] and its effect on verrucae plantaris. 1992
3. Robbins JE: Primary podiatric medical book. p. 301. WB Saunders, Philadelphia, 1994
4. Yale JF: Podiatric medicine, 3rd ed. Williams & Wilkins, Baltimore, 1987
5. Massing AM, Epstein WL: Natural history of warts: A two year study. Arch Dermatol 87:306-310, 1963
6. Cobb MW: Human papillomavirus infection. J Am Acad Dermatol 22:547-566, 1990
7. Androphy EJ: Human papillomavirus: Current concepts. Arch Dermatol 125:683-685, 1989
8. Shelley WB, Shelley ED: Advanced dermatologic therapy. WB Saunders, Philadelphia, 1987
9. Rees RB: The treatment of warts. Clin Dermatol 3:179-184, 1985
10. Bart BJ, Biglow J, Vance JC, et al: Salicylic acid in karaya gum patch as a treatment for verruca vulgaris. J Am Dermatol 20:74-76, 1989
11. Bunney MH, Nolan MW, Buxton PK, et al: The treatment of resistant warts with intralesional bleomycin: controlled clinical trial. Br J Dermatol 11:197-207, 1984
12. McBurney EL, Rosen DA: Carbon dioxide laser treatment of verrucae vulgares. J Dermatol Surg Oncol 10:45-48, 1984
13. Apfelberg DB, Druker D, Maser MR, et al: Benefits of the CO₂ laser for verruca resistant to other modalities of treatment. J Dermatol Surg Oncol 15:371-375, 1989

